

CASE REPORT

Electrical Cortical Stimulation of the Human Prefrontal Cortex Evokes Complex Visual Hallucinations

O. Blanke,* T. Landis,* and M. Seeck*^{†,1}

**Department of Neurology, University Hospital of Geneva, Laboratory of Presurgical Epilepsy Foundation, [†]Program of Functional Neurology and Neurosurgery from the University Hospitals Lausanne and Geneva, Switzerland*

Received July 5, 2000

Complex visual hallucinations are a well-known feature of electrical stimulation or epileptic discharge in the temporal lobe. It has been proposed that these visual hallucinations result from an electrical interference with the ventral visual processing stream in the lateral temporal lobe and the memory system in medial temporal structures, which explains their frequent visual and mnemonic features. Even though recent studies have demonstrated visual and memory functions in the prefrontal cortex, up to now epileptic discharge or electrical stimulation of prefrontal structures has only rarely been reported to induce visual phenomena. We report on two patients undergoing invasive presurgical epilepsy evaluation in which electrical cortical stimulation of the left prefrontal cortex repeatedly induced complex visual hallucinations. Interestingly, the induced visual responses differed with respect to their spatial organization: whereas those evoked on the inferior frontal gyrus were perceived in the whole visual field, complex visual responses on the middle frontal gyrus were restricted to the contralateral hemispace. Based on the spatial organization of the visual experiences in our patients, animal work, and neuroimaging data it might be suggested that specific subregions of the human prefrontal cortex might contain separate visual and mnemonic processing mechanisms. © 2000 Academic Press

Key Words: visual hallucination; visual processing; mnemonic processing; prefrontal cortex; human; epilepsy; intracranial electrodes.

INTRODUCTION

Complex visual hallucinations are a well-known feature of electrical cortical stimulation (ECS) or epileptic discharge in the temporal lobe and may be part of experiential phenomena that typically combine elements of complex visual perception and memory. Electrically induced visual hallucinations have been explained either as a negative effect resulting from a release phenomenon (1, 2) or as a positive effect causing activation of the underlying neuronal mechanisms (3–6). Gloor (5) has furthermore suggested that complex visual hallucinations result from electrical inter-

ference with the human homologue of the ventral object-processing stream as found in monkey (7). This hypothesis was based on the finding that neurons from the occipital lobe toward the temporal pole in primates are characterized by a progressive increase in complexity of receptive field properties (7–9). This latter finding is paralleled by the progressive increase in complexity of visual phenomena evoked by ECS of the homologous areas in human (10, 11). Since complex visual hallucinations can also be induced by ECS of the amygdala and the hippocampus, some authors have also postulated complex visual responses to originate in medial temporal lobe structures (1, 2).

Neuropsychological and neurophysiological studies in human and monkey, however, suggest the implication of the prefrontal cortex (PFC) in mnemonic and

¹ To whom correspondence should be addressed. Fax: +41-22-3728358. E-mail: margitta.seeck@hcuge.ch.



visual processing, especially with respect to the temporary storage of visual inputs and their selection and integration for action (12–14). Given the numerous anatomical connections between the PFC and temporal structures (15, 16) it is thus surprising that up to now epileptic discharge or ECS of prefrontal structures has only rarely been reported to induce visual phenomena. Bancaud and Talairach (17) as well as Chauvel *et al.* (18) reported that simple or complex visual hallucinations may be present as part of the semiology of seizures arising in the frontal lobe which are characterized mostly by nonlateralized elementary visual phenomena and only in rare instances by more complex “psychical” visual hallucinations. The latter phenomena were described as “impression of things in front of me” and “seeing my mother dead,” or as the perception of the “images of a person, always the same, always identical to an old friend” (all quotes from (18)). With respect to underlying prefrontal anatomy, complex visual hallucinations emanated mainly from the dorsolateral PFC, although unformed visual hallucinations were also reported during anterior cingulate seizure onsets. ECS of the dorsolateral PFC induced simple visual hallucinations, which were described as “dimming or intense brightening of the environment, uniform dull colors, or geometric images without spatial organization or movement” (19).

We had the opportunity to confirm and extend the observations of Halgren and Chauvel (19) and report on two patients undergoing invasive presurgical epilepsy evaluation in which ECS of the left PFC repeatedly induced *complex* visual hallucinations.

METHODS

Patient A.M.

Patient A.M. was a 27-year-old, ambidextrous woman who had drug-resistant seizures since the age of 12. Her seizures were characterized initially by an epigastric sensation followed by a complex auditory hallucination (the patient felt the presence of an unknown woman behind her on the right saying “no, no” or “don’t do that”), followed by an impairment of consciousness, staring, and oral as well as manual automatisms. Rarely generalized tonic-clonic seizures were noted. Right-sided hemiparesis and aphasia were observed during the postictal period. Family history as well as personal history were unrevealing. A seizure frequency of four to seven per week could not be altered by various anticonvulsive treatments.

Epilepsy surgery was finally considered and she was referred to our laboratory for long-term video EEG monitoring and complementary examinations. The neurological examination showed right-sided dysidiadochinesis and discrete right-sided hypoesthesia. Magnetic resonance imaging (MRI) demonstrated a left hemispheric, predominantly posterior atrophy, left hippocampal dysplasia, and aplasia of the splenium. Nuclear imaging and neuropsychological testing suggested left temporal dysfunction. Video-EEG recordings with 29 scalp and 2 sphenoidal electrodes suggested left hemispheric seizure onset. For a more detailed localization of the epileptic focus and its differentiation from motor and language cortex, chronic subdural recordings were carried out that showed left mesiotemporal seizure onset (see Fig. 1a). Left partial anterior temporal lobectomy was carried out and the patient has been seizure-free for more than 24 months.

Patient D.K.

This 18-year-old, right-handed woman started having seizures at the age of 7. The habitual seizures began with an impairment of consciousness and were followed by manual automatisms and a rightward deviation of the eyes and the head. Seizure frequency was 5–12 per week, often followed by secondary generalization. On admission, neurological examination was normal, as was MRI. Presurgical evaluation, including continuous video-EEG recording, nuclear imaging, and neuropsychological testing indicated left frontal epilepsy. Invasive monitoring was demanded to localize precisely the epileptic focus and to differentiate it from eloquent cortex. However, functional mapping resulted in speech arrest in close proximity to the epileptogenic focus and no complete resection could be carried out (Fig. 1b). During a follow-up period of 6 months, five habitual seizures outside the direct postoperative period occurred, corresponding to a marked reduction of her preoperative seizure frequency.

Intracranial Electrodes and Electrical Cortical Stimulation

In both patients subdural grid electrodes were implanted over the cortical surface to localize the epileptic focus, primary motor and somatosensory cortex, as well as language cortex (20, 21). In patient D.K. 96 electrodes and in patient A.M. 100 electrodes were placed over the surface of the left hemisphere, covering partly the lateral frontal and mesial frontal (only

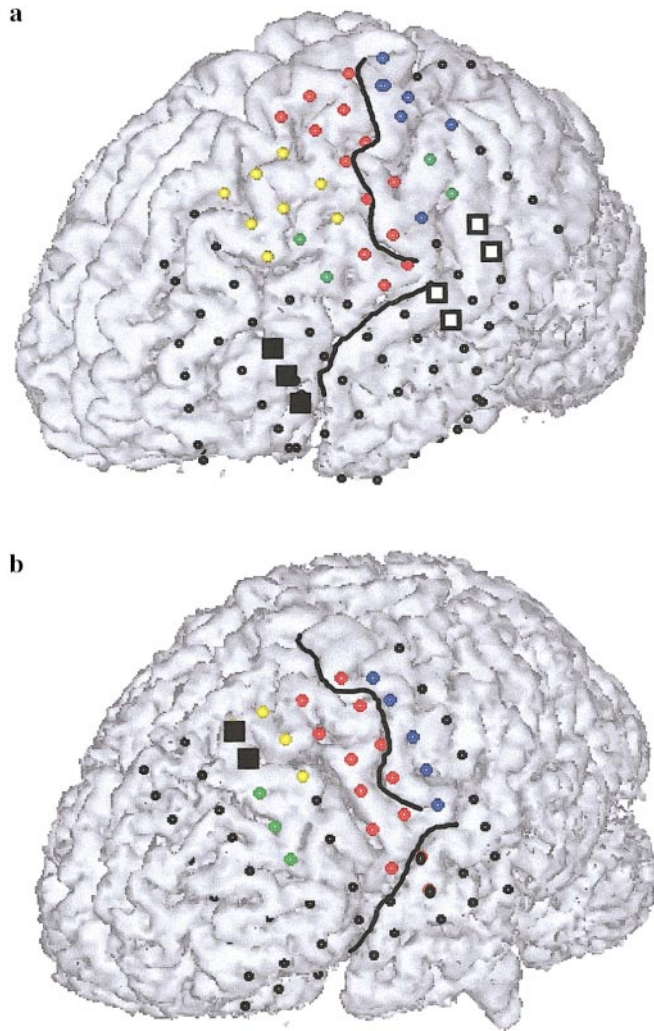


FIG. 1. Anatomical location of frontal electrodes. The three-dimensional MR images with the implanted electrodes are shown for patient A.M. (a) and patient D.K. (b) The behavioral responses as found by stimulation mapping are indicated as follows. Complex visual hallucination at frontal electrodes: black square; eye movements: yellow; other motor responses: red; somatosensory responses: blue; language responses: green. Black circles localized over the frontal cortex represent sites at which no overt responses were evoked. The central sulcus and the lateral sulcus are outlined (black lines). The letters refer to positions of stimulated electrodes on the grid. Each row is numbered from 1 to 8 (down to top, i.e., language responses evoked in patient A.M. over the frontal lobe at electrodes D5 and D6).

D.K.), lateral parietal, lateral and basal temporal, and temporooccipital (only A.M.) lobes. Subdural grid electrodes were MRI-compatible, 3-mm-diameter stainless-steel electrodes with a center-to-center distance of 0.8 cm. Electrodes were embedded in a clear Silastic sheet (Ad-Tech Corp., Racine, WI). Electrode

location was determined by intraoperative photographs and three-dimensional MRI (Fig. 1). At every electrode site ECS was started with an amplitude of 0.5 mA and incremented in 0.5-mA steps until a response, sensory or motor, was obtained. Alternating polarity square-wave stimuli (0.3-millisecond) were delivered at a repetition rate of 50 Hz, as described elsewhere (20, 22). Trains of stimulation were usually of 2- or 5-second duration (GRASS Stimulator S12, Grass Instruments, Quincy, MA). The EEG was recorded continuously during the stimulation procedure with a sampling rate of 200 Hz, bandpass 0.1–70 Hz. The occurrence and absence of electrical afterdischarges were noted. The recording and stimulation procedure was carried out with the patient sitting comfortably in bed, head unrestrained. The patient was asked to exactly indicate any sensory and motor percept elicited by ECS. ECS was carried out with both patients under their habitual anticonvulsant medication.

RESULTS

Stimulation mapping permitted definition of skeletal motor responses, oculomotor responses, somatosensory responses, as well as language responses in both patients (Fig. 1). Localization of these functions does not suggest grossly deviant brain pathology with respect to anatomical representations of cortical functions in the frontal, parietal, and temporal lobes in both patients.

Patient A.M.

In this patient complex visual hallucinations were induced at two adjacent sites in the prefrontal cortex on the inferior frontal gyrus (see Fig. 1a). ECS at site B3–B4 at 5.5 mA caused the patient to say: “All of a sudden it seems as if many things come to me, I can hardly see them [. . .] all at the same time, a church, a castle, a big room.” Stimulation was repeated at 6.0 and 6.5 mA and the patient described that “I feel that I’m in a castle” and “it is a little bit incoherent, like in dreams” and that “it seems to me that it is never the same subject, each time it is a different thing.” On questioning she described her sensations as neutral and said that “it leaves her totally unaffected, as if I would be outside things” and “as if the things would be passing me, I’m there, but I do not feel concerned, it is as if I would be watching TV and not paying attention to the film.” ECS at the

adjacent site, B2–B3, at 5.0 mA evoked a sensation that the patient described as “it seems to me as if a lot of thoughts are coming, but it seems to me as if I do not have the time to retain them all.” Stimulation at slightly higher currents (5.5 and 6.0 mA) caused her to say that “one could say that I have the impression that I was dancing, something like that [. . .]. It seemed to me as if I was seeing children dancing and that I was carrying my dance shoes in my hands.” Sensations were described as “no sounds, just images,” which were fast and short without affective tone. No afterdischarges were noted after stimulation at either site.

Patient D.K.

Stimulation of site C7–C8 immediately anterior to the sites where eye movements were induced (Fig. 1b (23)) and mesial to sites where speech arrest was elicited (C4–C5, C5–C6) resulted in the induction of a complex visual hallucination. With respect to gross anatomy this site was localized on the posterior part of the middle frontal gyrus. Synchronized with the ECS of the electrodes C7–C8 at 7.5 mA, she repeatedly reported the presence of a “young, tall man with short black hair in a white coat” in the neighboring room to her right, i.e., in the contralateral space with respect to the stimulated hemisphere. The sensation was described as “an idea or a thought, like dreaming.” The room in which she located the man was the adjacent EEG laboratory, the door of which was closed at the time of stimulation. No visual phenomena were reported in the left visual field. At higher stimulation currents (8.5–10.5 mA) the hallucination was identical but now accompanied by contralateral saccadic eye movements. No afterdischarges were elicited. At the electrode sites posterior to C7–C8, the human frontal eye field was localized and ECS induced contralateral saccades and smooth eye movements at much lower currents (1.5 and 4.5 mA; see (23)).

Complex sensory responses are not as objective as measured neuronal activity or evoked motor responses: they are experienced subjectively and described verbally from patient to clinician. However, the fact that visual responses were repeatedly reported by both patients timelocked with ECS, even though they did not know onset and duration of the stimulation train, makes us confident about their cerebral origin.

DISCUSSION

In both patients ECS of the PFC induced complex hallucinations characterized by the vivid perception of scenes including human figures. Although some reports have described visual hallucinations induced by stimulation of the PFC (17–19), our data demonstrate that ECS of the left PFC may repeatedly induce complex visual hallucinations similar to those that have classically been observed after ECS of the temporal lobe (1–6, 24). Moreover, we found the spatial organization of the induced response to be different depending on the site of stimulation within the PFC: The visual responses evoked on the inferior frontal gyrus were perceived in the whole visual field (as in temporal lobe stimulation), whereas the visual responses on the middle frontal gyrus, bordering the superior frontal sulcus and anterior to the frontal eye field (23), were restricted to the contralateral hemisphere. Unilateral complex visual hallucinations have been reported after occipital lobe stimulation, but not in other cortical structures (25, 26).

As receptive field properties of single neurons—from the primary visual cortex to the visual association cortex in the temporal lobe—show a progressive increase in complexity (8), evoked visual responses from the respective areas in human are as well characterized by a progressive increase in complexity (10, 11). Following Gloor (5), complex visual hallucinations result from an electrical interference of the human homologue of the ventral visual object-processing stream (7). However, the anatomical framework for artificially induced visual hallucinations needs to be extended since it does not account for the visual hallucinations reported by previous authors (19) and evoked in our patients by electrically stimulating the PFC. The implication of the PFC in mnemonic and visual processing has repeatedly been demonstrated, especially with respect to working memory and processing of visual information (12–14). Work by Goldman-Rakic and collaborators (27–29) has shown that neurons in the PFC are characterized by visual receptive fields much as single neurons in the temporal lobe, providing an explanation for the visual character of the hallucinations in our patients. By using visually triggered activity during memory delays, these physiological studies have demonstrated the implication of the dorsolateral PFC in visuospatial processes and of the ventrolateral PFC in processes related to object vision (28, 29). Hence, these studies proposed an extension of both visual processing streams onto the

PFC. In humans, the implication of the PFC in visual and mnemonic processing has also been suggested by lesion studies (12) as well as neuroimaging studies (30, 31). Recently, Courtney *et al.* (32) were able to dissociate spatial visual processing from object-related visual processing within the human PFC. Courtney *et al.* suggest a predominant implication of the cortex at the posterior half of the superior frontal sulcus in working memory for the spatial position of visual stimuli and an area on the inferior frontal gyrus in working memory for visual object features such as faces. Interestingly, the region involved in spatial processing of visual information was localized anterior to the frontal eye field (23, 33). This is a remarkably similar finding if compared with our patient D.K. in whom we induced unilateral visual hallucinations anterior to sites whose stimulation evoked contralateral eye movements. Moreover, this anatomicofunctional organization in human as found by neuroimaging and ECS is very similar if compared with the monkey PFC where an area important for visuospatial memory processing (27, 28, 34) is located immediately anterior to the electrically defined frontal eye field (35). Visual activity in both prefrontal areas has furthermore been shown to be characterized in monkey and human by a strong preference for stimuli in the contralateral hemifield (22, 27) and, thus, the visual half-field in which patient D.K. perceived the complex visual scene. To reiterate, single-unit recordings in the monkey as well as functional imaging and ECS in human present converging evidence for the implication of the dorsolateral PFC in visuospatial processing and the ventrolateral PFC in visual object processing. It might thus be suggested that ECS of neurons in the temporal lobe and the ventrolateral PFC induce visual responses that are perceived in the whole visual field and ECS in the dorsolateral PFC evokes responses restricted to the contralateral visual field. Given the rarity of our finding and the fact that the observed dissociation between visual responses evoked from the respective areas was not found within single patients, the latter conclusion should be regarded with caution and requires further confirmation in humans.

Inherent to our method is the combined stimulation of neurons and white matter pathways under the stimulating electrode. We thus cannot exclude that our observation is related to the activation of anatomical connections between the PFC and the parietal and the temporal lobes as well as limbic structures (15, 16). Via these anatomical connections, the visual responses might also stem from an electrical interference with an extended cortical network including some or even all

of the aforementioned structures. However, the visual responses obtained were focal responses and clearly dissociated from responses evoked at adjacent sites (contralateral eye movements and language responses in patient D.K., language responses in patient A.M.). Results obtained in epileptic patients have to be applied carefully to normal brain function. However, it should be pointed out that the mapping of motor and language functions confirmed normal representation of cortical functions in both patients. Furthermore, the epileptic focus in patient A.M. was localized in the temporal lobe and was confined in patient D.K. to more anterior prefrontal regions. The areas under investigation thus did not coincide with the epileptic focus.

Given the left frontal site of stimulation and the description of the visual hallucinations as “dreams” or “thoughts” (in patient A.M. even as a multitude of thoughts), it might be suggested that the reports in our results are not complex visual hallucinations but rather forced thinking: a psychic aura characterized by recurrent intrusive thoughts, ideas, or urges to act or to speak (10, 36, 37). However, several lines of evidence argue against this hypothesis. First, the few reported patients suffering from forced thinking are commonly exposed to an identical recurrent thought about a specific phrase such as “tell me yes” or “why can’t you have a seizure” (both quotes from (37)) or about actions as “I need to grab something” (37) or “[I] told somebody [. . .] to do this or that” (10). These phenomena were clearly not experienced in the passive visual sensations of our patients. Second, neither our patients nor the clinicians reported speech deficits, which commonly accompany or follow intrusive thoughts during forced thinking (10, 36, 37). Finally, the descriptions of patients suffering from forced thinking are void of sensory sensations.

ACKNOWLEDGMENT

This work was supported by the Swiss National Science Foundation (Grants 31-52933.97 and 4038-044081).

REFERENCES

1. Jackson JH, Stewart P. Epileptic attacks with a warning of a crude sensation of smell and with the intellectual aura (dreamy state) in a patient who had symptoms pointing to gross organic disease of the right temporo-sphenoidal lobe. *Brain* 1899;22: 534–49.

2. Halgren E, Walter RD, Cherlow DG, Crandall PH. Mental phenomena evoked by electrical stimulation of the human hippocampal formation and amygdala. *Brain* 1978;101:83–117.
3. Penfield W. The role of the temporal cortex in certain psychical phenomena. *J Ment Sci* 1955;101:451–65.
4. Gloor P, Olivier A, Quesney LF, Andermann F, Horowitz S. The role of the limbic system in experiential phenomena of temporal lobe epilepsy. *Ann Neurol* 1982;12:129–44.
5. Gloor P. Experiential phenomena of temporal lobe epilepsy: facts and hypotheses [review]. *Brain* 1990;113:1673–94.
6. Bancaud J, Brunet-Bourgin F, Chauvel P, Halgren E. Anatomical origin of déjà vu and vivid memories in human temporal lobe epilepsy. *Brain* 1994;117:71–90.
7. Ungerleider LG, Mishkin M. Two cortical visual systems. In: Ingle DJ, Goodale MA, Mansfield RJW, editors. *Analysis of visual behavior*. Cambridge: MIT Press, 1982: 549–86.
8. Felleman DJ, Van Essen DC. Distributed hierarchical processing in the primate cerebral cortex. *Cereb Cortex* 1991;1:1–47.
9. Desimone R, Duncan J. Neural mechanisms of selective visual attention. *Annu Rev Neurosci* 1995;18:193–222.
10. Penfield W, Jasper H. *Epilepsy and the functional anatomy of the human brain*. London: Churchill, 1954: 116–26.
11. Penfield W, Perot P. The brain's record of auditory and visual experience: a final summary and discussion. *Brain* 1963;86:595–696.
12. Stuss DT, Eskes GA, Foster JK. Experimental neuropsychological studies of frontal lobe functions. In: Boller F, Grafman J, editors. *Handbook of Neuropsychology*, Vol 9. Amsterdam: Elsevier Science, 1994: 149–85.
13. Goldman-Rakic PS. Regional and cellular fractionation of working memory. *Proc Natl Acad Sci USA* 1996;93:13473–80.
14. Miller EK. The prefrontal cortex: complex neural properties for complex behavior. *Neuron* 1999;22:15–17.
15. Goldman-Rakic PS, Selemon LD, Schwartz ML. Dual pathways connecting the dorsolateral prefrontal cortex with the hippocampal formation and parahippocampal cortex in the rhesus monkey. *Neuroscience* 1984;12:719–43.
16. Barbas H. Architecture and cortical connections of the prefrontal cortex in the rhesus monkey. In: Chauvel P, Delgado-Escueta AV, Halgren E, Bancaud J, editors. *Advances in Neurology*, Vol 57: Frontal Lobe Seizures and Epilepsies. New York: Raven Press, 1992: 91–115.
17. Bancaud J, Talarach J. Clinical semiology of frontal lobe seizures. In: Chauvel P, Delgado-Escueta AV, Halgren E, Bancaud J, editors. *Advances in Neurology*, Vol 57: Frontal Lobe Seizures and Epilepsies. New York: Raven Press, 1992: 3–58.
18. Chauvel P, Kliemann F, Vignal JP, Codhiewicz JP, Talarach J, Bancaud J. The clinical signs and symptoms of frontal lobe seizures: phenomenology and classification. In: Jasper HH, Riggio S, Goldman-Rakic PS, editors. *Advances in Neurology*, Vol 66: Epilepsy and the Functional Anatomy of the Frontal Lobes. New York: Raven Press, 1995: 115–26.
19. Halgren E, Chauvel P. Experiential phenomena evoked by human brain stimulation. In: Devinsky O, Beric A, Dogali M, editors. *Advances in Neurology*, Vol 63: Electrical and Magnetic Stimulation of the Brain and Spinal Cord. New York: Raven Press, 1993: 123–40.
20. Lesser RP, Lueders H, Klem G, Dinner DS, Morris HH, Hahn JF, Wyllie E. Extraoperative cortical functional localization in patients with epilepsy. *J Clin Neurophysiol* 1987;4:27–53.
21. Ojeman GA, Sutherland WW, Lesser RP, Dinner DS, Jayakar P, Saint-Hilaire JM. Cortical stimulation. In: Engel J, editor. *Surgical Treatment of the Epilepsies*. New York: Raven Press, 1994: 399–414.
22. Blanke O, Morand S, Thut G, Michel CM, Spinelli L, Landis T, Seeck M. Visual activity in the human frontal eye field. *NeuroReport* 1999;10:925–30.
23. Blanke O, Spinelli L, Thut G, Michel CM, Perrig S, Landis T, Seeck M. Location of the human frontal eye field as defined by electrical cortical stimulation: anatomical, functional and electrophysiological characteristics. *NeuroReport* 11:763–72.
24. Jackson JH. On a particular variety of epilepsy 'intellectual aura', one case with symptoms of organic brain disease. *Brain* 1888;11:179–207.
25. Williamson PD, Thadani VM, Darcey TM, Spencer DD, Spencer SS, Mattson RH. Occipital lobe epilepsy: clinical characteristics, seizure spread patterns, and results of surgery. *Ann Neurol* 1992;31:3–13.
26. Salanova V, Andermann F, Olivier A, Rasmussen T, Quesney LF. Occipital lobe epilepsy: electroclinical manifestations, electrocorticography, cortical stimulation and outcome in 42 patients treated between 1930 and 1991: surgery of occipital lobe epilepsy. *Brain* 1992;115:1655–80.
27. Funahashi S, Bruce CJ, Goldman-Rakic PS. Mnemonic coding of visual space in the monkey's dorsolateral prefrontal cortex. *J Neurophysiol* 1989;61:331–49.
28. Wilson FAW, O'Scalaidhe SPO, Goldman-Rakic PS. Dissociation of object and spatial processing domains in primate prefrontal cortex. *Science* 1993;260:1955–7.
29. O'Scalaidhe SPO, Wilson FAW, Goldman-Rakic PS. Areal segregation of face-processing neurons in prefrontal cortex. *Science* 1997;278:1135–8.
30. McCarthy G, Blamire AM, Puce A, Nobre AC, Bloch G, Hyder F, Goldman-Rakic P, Shulman RG. Functional magnetic resonance imaging of human prefrontal cortex activation during a spatial working memory task. *Proc Natl Acad Sci USA* 1994; 91:8690–4.
31. Owen AM, Milner B, Petrides M, Evans AC. Memory for object features versus memory for object location: a positron-emission tomography study of encoding and retrieval processes. *Proc Natl Acad Sci USA* 1996;93:9212–7.
32. Courtney SM, Petit L, Maisog JM, Ungerleider LG, Haxby JV. An area specialized for spatial working memory in human frontal cortex. *Science* 1998;279:1347–51.
33. Paus T. Location and function of the human frontal eye-field: a selective review. *Neuropsychologia* 1996;34:475–83.
34. Boch RA, Goldberg ME. Participation of prefrontal neurons in the preparation of visually guided eye movements in the rhesus monkey. *J Neurophysiol* 1989;61:1064–84.
35. Bruce CG, Goldberg ME. Primate frontal eye fields. I. Single neurons discharging before saccades. *J Neurophysiol* 1985;53: 606–35.
36. Ward CD. Transient feelings of compulsion caused by hemispheric lesions: three cases. *J Neurol Neurosurg Psychiatry* 1988;51:266–8.
37. Mendez MF, Chierri MM, Perryman KM. Epileptic forced thinking from left frontal lesions. *Neurology* 1996;47:79–83.